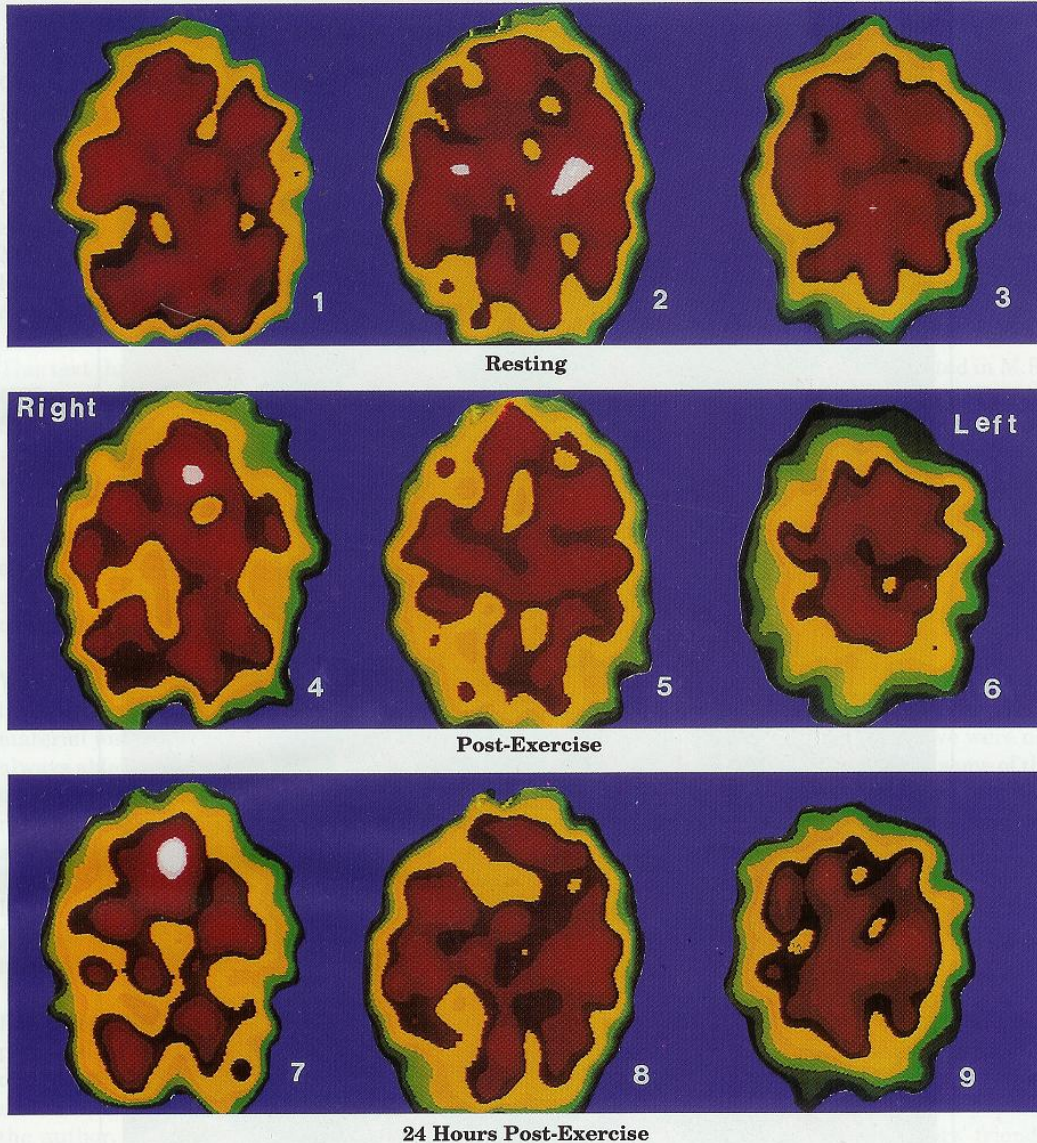


M.E. Patient Exercise - Consequences upon Brain Blood Flow

The Clinical and Scientific Basis of M.E. / CFS

The Negative Effects of Exercise on an M.E./CFS Dysfunctional Brain

These Xenon SPECT scans of a 37 year-old female M.E./CFS patient and the concept were provided by Dr. Jay Goldstein of Anaheim, California. The technical expertise is that of Dr. Ismael Mena, UCLA Harbor, California.



Resting State Images 1, 2 and 3, represent the abnormal resting state of an M.E./CFS brain. There is a perfusion defect in the left inferior frontal lobe as well as the right and left posterior parietal lobes.

Immediate Post-Exercise State Images 4, 5 and 6 represent the immediate post-exercise function of the brain of the same patient. There is a significant decrease in perfusion of the right and left frontal lobes and the right and left posterior parietal lobes. An occipital perfusion defect is starting to appear. The functional resting defects noted in images 1, 2 and 3 have become aggravated.

24 Hours Post-Exercise State Images 7, 8 and 9 illustrate the severely decreased brain perfusion of the same patient 24 hours after the brain has been stressed by physical exercise. This 24 hour delayed effect may explain much of the M.E./CFS dysfunction that occurs the day after exercise or other stress factors.

The pathological brain changes demonstrated in 1, 2 and 3 were exaggerated by normal physical activity. Similar dysfunctional images could probably be produced in an M.E./CFS patient as a result of sleep deprivation, a secondary infectious state, cognitive, sensory or emotional factors. A normal healthy patient will probably exhibit increased brain perfusion after similar modest exercise. See Dr. Goldstein, Addendum I, showing common stress pathway.

Source: *The Clinical and Scientific Basis of ME/CFS*,
Byron M Hyde M.D. ISBN: 0-969-5662-0-4.
www.nightingale.ca/

vii